

Immunohistochemical Evaluation of Calretinin in Ameloblastoma, Odontogenic keratocyst and Dentigerous Cyst

Siva Sukumaran Prasanna, Padmakumar Sreenivasan Kamala

ABSTRACT

Background: Calretinin plays an important role in calcium signalling and naturally expressed in nervous tissues. Various studies suggest that calretinin may involve in amelogenesis. Calretinin also seems to have role in tumorigenesis since it regulates apoptosis.

Aim: To find out whether there is any variation in expression of calretinin in Ameloblastoma, Odontogenic keratocyst and Dentigerous cyst.

Materials & Methods: A total of 50 samples each from Ameloblastoma, odontogenic keratocyst and Dentigerous cyst were retrospectively studied. The immunohistochemical expression of calretinin was assessed by using calretinin antibody.

Results: Chi square test was used to compare categorical parameters between groups. Kruskal Wallis Test and Mann-Whitney U Test were carried out to compare quantitative parameters among the groups. Statistically, significant values were obtained when comparing the immunohistochemical expression of calretinin in various odontogenic lesions studied and it was highest in ameloblastoma followed by OKC. None of the cases of dentigerous cyst were immunopositive for calretinin.

Conclusion: There was statistically significant variation in the expression of calretinin among ameloblastoma, OKC and dentigerous cyst and it contributes to the aggressiveness of those lesions.

Keywords: Ameloblastoma, Calretinin, Dentigerous cyst, Immunohistochemistry, Odontogenic keratocyst.

Oral and Maxillofacial Pathology Journal (2022): <https://www.ompj.org/archives>

INTRODUCTION

Odontogenic cysts and tumours are aberrations at some stage of odontogenesis¹. The origin of odontogenic tumours is mostly from the tooth forming apparatus, arising from the epithelium, ectomesenchyme/mesenchyme, or a mixture of both. Odontogenic cysts (OCs) develop mainly from the proliferation and cystic degeneration of the odontogenic epithelial remnants².

Calretinin is regarded as the most extensively expressed calcium-binding protein in central and peripheral neural tissues. Various studies conducted to date in rats have indicated the appearance of calretinin in neural elements of the tooth pulp and periodontal ligament and in the epithelium-derived tissues during odontogenesis in rat molar tooth germs. This suggests that this protein may play a vital role in the formation of enamel. Although the exact biological function of calretinin remains unknown, its possible roles as a calcium buffer, calcium sensor and regulator of apoptosis have been postulated in many previous studies³. Calretinin also seems to possess a role in the regulation of expression of growth factors and involvement in cell proliferation, differentiation, and neoplastic transformation⁴.

Due to calretinin's widespread distribution in many normal and neoplastic human tissues and its presence in the odontogenic epithelium during odontogenesis, it could have also been expressed in cystic and neoplastic odontogenic tissues. All these suggest that calretinin could have some application in the differential diagnosis of odontogenic tumours and cysts⁵. Therefore,

Department of Oral Pathology and Microbiology, Government Dental College, Thiruvananthapuram, Kerala, India

Corresponding author: Siva Sukumaran Prasanna, Government Dental College, Thiruvananthapuram, Kerala, India. E-mail address: sivaprasannagopika@gmail.com

How to cite this article: Prasanna SS, Kamala PS. Immunohistochemical Evaluation of Calretinin in Ameloblastoma, Odontogenic keratocyst and Dentigerous Cyst. Oral MaxillofacPathol J 2022; 13(2): page no. 82-86

Source of Support: Nil

Conflict of Interest: None

Acknowledgement: I gratefully acknowledge Prof. Dr. Padmakumar S.K., for the valuable suggestions which have contributed greatly to the improvement of the thesis. I thank Dr. Oommen P. Mathew for his valuable inputs and support for the statistical part of my thesis. I would also like to thank Mr. Rajesh from Pathnsitu Biotechnologies Pvt. Ltd. for supplying the necessary chemicals and immunohistochemical marker needed for my research.

further assessment of molecular aspects and immunohistochemical expression of calretinin in neoplastic tissues is essential to provide a better understanding of the biological behaviour, influencing factors, and tumourigenesis of odontogenic neoplasms⁶.

Ameloblastoma is the most frequently encountered benign,

locally aggressive neoplasm arising from the enamel organ⁷. The most commonly occurring odontogenic cysts are radicular cysts, dentigerous cysts, and odontogenic keratocyst (OKC)^{8,9}. Various studies have shown calretinin positivity in aggressive areas of both ameloblastoma and OKC³. To the best of our knowledge, there are only a few previous studies on the immunohistochemical expression of calretinin in odontogenic lesions. The present study was done to assess the variation in the immunohistochemical expression of calretinin in ameloblastoma, OKC, and dentigerous cyst.

MATERIALS & METHODS

A total of 150 formalin fixed, paraffin embedded tissue blocks were taken from the archives of the department of Oral Pathology & Microbiology. They included 50 histopathologically proven cases each of ameloblastoma, OKC and dentigerous cyst.

The sections of 4 micrometer thickness were transferred to aminopropyl epoxy saline coated slides. The slides with tissue sections were treated with three changes of xylene, followed by descending grades of alcohol and rehydration with water. The slides were then transferred to citrate buffer and autoclaved for antigen retrieval at 15 lbs pressure for 15 min. The slides were allowed to cool and washed in phosphate buffer solution (pH 7.2) for 5 min. Peroxidase and protein blocking were done using 3% hydrogen peroxide and protein block reagent, respectively, for 10 min each. The slides were incubated with concentrated, rabbit polyclonal anticalretinin antibody for 30 minutes. The secondary antibody used was an enhancer followed by streptavidin solution for 20 min. A drop of freshly prepared 3'-diaminobenzidine tetrahydrochloride was added. Three

changes of PBS washes were performed after every step during the immunostaining procedure. The sections were counterstained with hematoxylin and mounted with DPX.

The findings were then observed under a conventional light microscope (Labomed, India). Brown colour staining, both nuclear and cytoplasmic, was considered as positive staining and expression of calretinin. Calretinin Labelling Index was calculated by dividing the number of positive cells by the total number of cells counted in the slide and expressed as percentage. A minimum of thousand cells was counted for each slide. The cytoplasmic staining intensity was evaluated and graded as mild (+), moderate (++), and intense (+++) as described. Mild staining is denoted by light brown colour, moderate by brown colour, and intense by dark brown colour. The cells that did not take up any brown stain are considered negative.

Data obtained from the above methodology was updated to excel data sheet and was analysed using the computer software, Statistical Package for Social Sciences version 16. Chi square test was used to compare categorical parameters among different odontogenic lesions such as ameloblastoma, OKC and dentigerous cyst. Kruskal Wallis Test and Mann-Whitney U Test were used to compare quantitative parameters among the groups. $P < 0.05$ was considered the threshold for statistical significance.

RESULTS

All cases of ameloblastoma (100%) showed immunopositivity for calretinin (Figure 2) whereas only 7 cases of OKC showed immunopositivity for calretinin and it accounted for 14% (Figure 3). It is also evident that none of the cases of dentigerous cyst (0%)

Table 1: Calretinin immunopositive expression in Ameloblastoma, OKC and Dentigerous cyst

Calretinin Immuno-expression	Ameloblastoma		OKC		Dentigerous cyst		χ^2	P
	Count	Percent	Count	Percent	Count	Percent		
Absent	0	0.0	43	86.0	50	100.0	123.62	$P < 0.01$
Present	50	100.0	7	14.0	0	0.0		

Table 2: Comparison of the expression of calretinin in Ameloblastoma, OKC and Dentigerous cyst

No of CAL +VE cells	Mean	SD	Median	χ^2	Sig.	Mann-whitney U Test		
						Pair	z	P
Ameloblastoma (A)	524.0	123.5	550.0	119.98	$P < 0.01$	A & B	8.14	$P < 0.01$
OKC (B)	65.6	165.1	0.0			A & C	9.23	$P < 0.01$
Dentigerous cyst (C)	0.0	0.0	0.0			B & C	2.73	$P < 0.01$

§ Kruskal Wallis Test

Table 3: Comparison of staining intensity of calretinin in Ameloblastoma, OKC and Dentigerous cyst

Staining intensity	Ameloblastoma		OKC		Dentigerous Cyst		χ^2	P
	Count	Percent	Count	Percent	Count	Percent		
Intense	15	30.0	2	4.0	0	0.0	114.17	$P < 0.01$
Mild	13	26.0	3	6.0	0	0.0		
Moderate	22	44.0	2	4.0	0	0.0		
Negative	0	0.0	43	86.0	50	100.0		



showed immunopositivity for calretinin (Table 1). According to the statistical analyses this variation in the expression of calretinin in ameloblastomas, OKCs and dentigerous cysts was significant ($P < 0.01$).

Comparison of calretinin expression in various odontogenic lesions was done using Kruskal Wallis Test. A statistically significant P value was obtained ($P \text{ value} < 0.01$). Intergroup comparison between dentigerous cysts and OKCs, OKCs and ameloblastomas and between ameloblastomas and dentigerous cysts groups were done using Mann-whitney U Test. There was statistically significant variation in expression of calretinin between ameloblastoma and OKC ($P < 0.01$), ameloblastoma and dentigerous cyst ($P < 0.01$) and OKC and dentigerous cyst ($P = 0.006$). According to results it becomes evident that the calretinin expression was highest in ameloblastoma, less in OKC and no expression in dentigerous cyst (Table 2) (Figure 1).

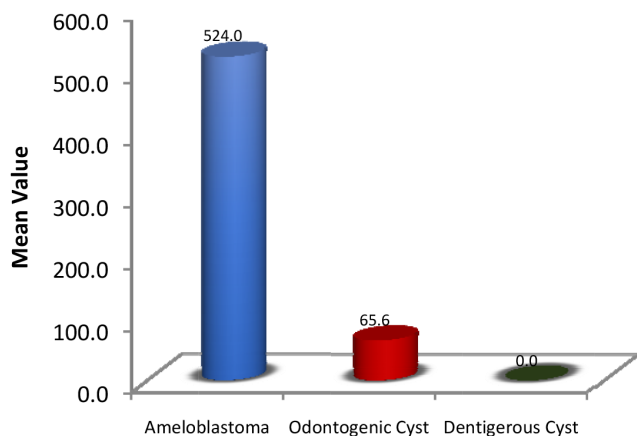


Fig. 1: Bar diagram showing comparison of the expression of calretinin in Ameloblastoma, OKC and Dentigerous cyst

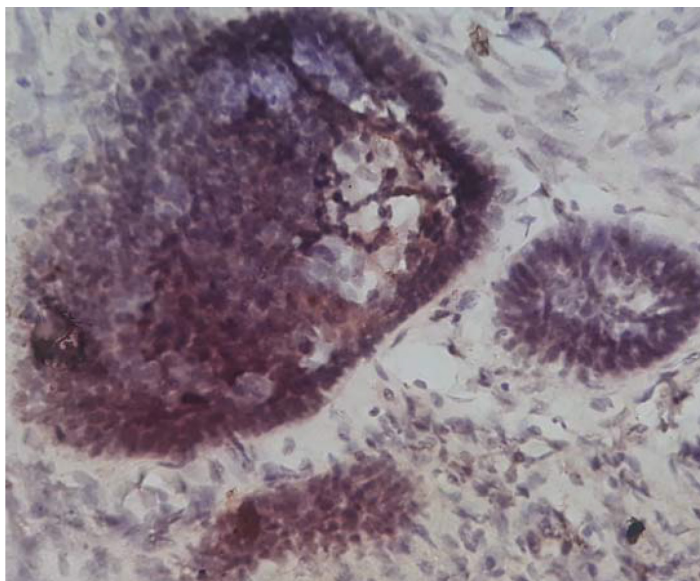


Fig. 2: Photomicrograph showing positive calretinin expression in Ameloblastoma. Immunohistochemistry, x10

There is variation in the staining intensity of calretinin among ameloblastoma, OKC and dentigerous cyst. It can be seen that in ameloblastoma 30% of cases showed intense staining, 44% of cases showed moderate staining and 26% of cases showed mild staining. None of the cases of ameloblastoma showed negative staining. In OKC 86% of cases showed negative staining. Among the positive cases 4% cases showed intense staining, 6% cases showed mild staining and 4% cases showed moderate staining. All cases of dentigerous cysts showed negative staining (Table 3). There was a statistically significant variation in staining intensity of calretinin between ameloblastomas and OKCs ($P < 0.01$), ameloblastomas and dentigerous cysts ($P < 0.01$) and OKCs and dentigerous cysts ($P = 0.006$).

DISCUSSION

The origin of odontogenic lesions is from the odontogenic epithelium or ectomesenchyme by the process of inductive tissue interaction¹⁰. The exact mechanisms that give rise to the proliferation of the odontogenic epithelial rests are obscure, however various subcellular and developmentally related factors might be responsible for their differentiation¹¹. The destructive nature of OKCs makes them unique among cysts. When compared to ameloblastoma, it has a less destructive behaviour. If the tissue sample is small and the neoplastic epithelium displays reactive changes induced by inflammation, the similarities between ameloblastoma and OKC in the clinical and radiographic features may also be mirrored at the histologic level. Although the histopathological features of both the OKC and ameloblastoma are diverse, both denote an aberration during the process of odontogenesis⁷.

Calcium, a ubiquitous second messenger directly or indirectly regulates a large number of biological processes. Calcium-binding proteins transmit calcium signals into the intracellular response which result in the regulation of many cellular activities¹³. Calretinin functions as a calcium buffer, sensor, and antiapoptotic factor. The possible role of calretinin protein in enamel formation can be linked to the wide expression of this protein during odontogenesis in the

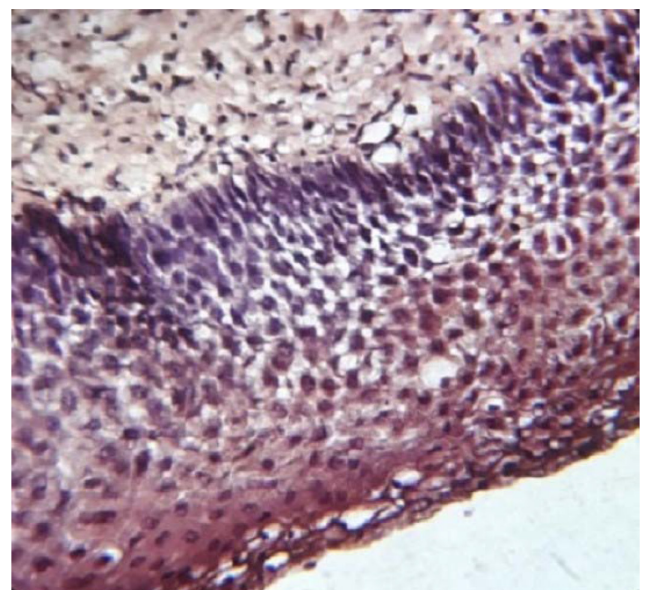


Fig. 3: Photomicrograph showing positive calretinin expression in OKC. Immunohistochemistry, x40

inner enamel epithelium and presecretory ameloblasts³. Calretinin is mostly expressed during the differentiation stage of amelogenesis but no previous studies have reported its expression in secretory or maturation stages¹⁴.

The present study was able to obtain calretinin immunopositivity in all the 50 cases (100%) of ameloblastoma and 7 cases (14%) of OKC whereas all the 50 cases of dentigerous cysts were negative for calretinin. The incongruity in immunoreactivity among the selected odontogenic lesions (higher immunoreactivity for ameloblastoma, less reactivity for OKC, and nonreactivity for dentigerous cysts) can be attributed to their diverse clinical and histopathological characteristics³.

In the present study, 14% of OKC cases showed positive calretinin immunoexpression and they showed an aggressive biological behaviour. Clinically, these lesions present with swelling and pain whereas lesions immunonegative for calretinin were asymptomatic. Radiologically, most of them appear as multilocular radiolucency and showed buccal expansion as well as displacement of adjacent teeth in contrast with lesions showing negative calretinin immunoexpression. Histologically, these lesions showed a greater mitotic activity in the parabasal layers of the lining epithelium compared to lesions showing negative calretinin immunoexpression. Therefore, it was evident that positive calretinin immunoexpression reflects the aggressive biological characteristics of the OKCs.

None of the cases of dentigerous cysts were immunopositive for calretinin. Since dentigerous cyst arises from reduced enamel epithelium, calretinin has no role in calcium transport. Hence the expression of this protein will also be minimal.

In convergence to the previous studies,^{3,4,6,15-19} the present study showed 100% positive staining of ameloblastomas. These studies did not observe positive calretinin staining in OKCs except for few studies^{3,15} in which OKCs showed 13% and 40% calretinin immunopositivity respectively. The present study showed no calretinin immunopositivity in dentigerous cysts which was in agreement with the previous studies' findings.

In disparity to the study conducted by Adriano et al^{20,7} OKCs (14%) in the present study showed immunopositivity to calretinin. As the sample size of the previous study was not robust, the slightly higher proportion of calretinin immunopositivity in OKCs (66%) raise a concern regarding the external validation of the study findings.

Vipulet al²¹ documented calretinin immunoexpression in 92% of OKC and 66.6% of ameloblastoma indicating their aggressive and neoplastic nature. They concluded that calretinin can be used as a marker to predict the biological behaviour and proliferation of OKC and ameloblastoma which helps in their treatment and prognosis. In divergence to this study, the sample size of the present study was adequate which increases the external validity of the study findings.

According to Altiniet al⁵, the higher the differentiation of the epithelium, the lesser the expression of calretinin. They found little or no immunostaining in those ameloblastomas that were lined by typical ameloblastic epithelium, while the epithelium with atypical ameloblastic features frequently expressed calretinin. But this finding was not in conjunction with our study results.

In convergence to the study conducted by Anilaetal²², the present study observed calretinin immunopositivity in ameloblastoma and aggressive areas of OKC and concluded that the key mechanisms resulting in the varied expression of calretinin in them were

mainly due to its role as an apoptotic and cell cycle regulator.

Amruthaetal²³, observed 100% of immunopositivity for calretinin ameloblastomas and this finding was in consistent with the present study. However, OKCs did not show positivity for calretinin, which can be attributed to an inadequate sample size of OKCs. They suggest there might be an aberrant expression of the calretinin gene even in OKCs. However, the variation in the extent of gene mutation could be the reason for the difference in the immunoexpression of calretinin stated in different studies.

Aggressive odontogenic tumours such as ameloblastic carcinomas and odontogenic myxomas were not included in this study. Therefore, future studies should target to determine the possible role of calretinin in the pathogenesis of these tumours which can help in using this protein for the treatment.

In contrary to the previously published studies, the strength of this study arises from the fact that the sample size used is adequate which increases the external validity of the study findings.

CONCLUSION

The present study assessed the immunohistochemical expression of calretinin in ameloblastomas, OKCs and dentigerous cysts. Immunopositivity of calretinin was highest in ameloblastoma followed by OKC. However, none of the cases of dentigerous cyst showed immunopositivity for calretinin. The increased immunohistochemical expression of calretinin commensurate with the obvious biological behaviour of the odontogenic lesions and is related to the aggressiveness of the lesions. The present study shows the importance of calretinin as a specific immunohistochemical marker for neoplastic ameloblastic epithelium. The variable expression of calretinin in ameloblastoma and OKC indicates that the higher the expression of the protein, the least differentiated will be odontogenic epithelium. Thus, the calretinin expression is stronger in ameloblastoma and weaker in OKC. According to this study, calretinin can be used as an immunohistochemical marker to predict the biological behaviour and proliferation of OKC and ameloblastoma which helps in their treatment and prognosis.

REFERENCES

1. Shafer's textbook of Oral Pathology Elsevier India; 2009. Shafer.
2. Imran A, Jayanthi P, Tanveer S, Gobu S. Classification of odontogenic cysts and tumors - Antecedents. *J Oral Maxillofac Pathol.* 2016;20(2):269-71.
3. Imran A, Tanveer S, Ranganathan K, Rao UDK, Joshua E. Expression of calretinin and cytokeratin 19 in radicular cyst, dentigerous cyst, odontogenic keratocyst, and ameloblastoma. *Journal of Dr. NTR University of Health Sciences.* 2016 Apr 1;5(2):118. *J Dr NTR Univ Heal Sci.* 2016;5:118-22.
4. Anandani C, Metgud R, Singh K. Calretinin as a Diagnostic Adjunct for Ameloblastoma. *Patholog Res Int.* 2014;2014:1-7.
5. Altini M, Coleman H, Doglioni C, Favia G, Maiorano E, Patologica I. Calretinin expression in ameloblastomas. *Histopathology.* 2000;37:27-32.
6. Thakre GR1, Desai RS2, Mamatha GS Reddy3 CS. Role of Calretinin in the Pathogenesis of Odontogenic Cysts and Tumors. *Sch J Dent Sci.* 2017;4(8):362-8.
7. Fukumashi K, Enokiya Y, Inoue T. Cytokeratins expression of constituting cells in ameloblastoma. *Bull Tokyo Dent Coll.* 2002;43(1):13-21.
8. Browne RM. The pathogenesis of odontogenic cysts: a review. *J Oral Pathol Med.* 1975;4(1):31-46.
9. Shear M SP. Cysts of the Oral and Maxillofacial Regions FE 2008. 6-58 p. Cysts of the Oral and Maxillofacial Regions, Fourth Edition [Internet]. 2008. 6-58 p.



10. Reichart PA PHOT and AL, 5th ed. Surrey UKQ 2004. p. 8.Reichart.
11. Taylor AM. New findings and controversies in odontogenic tumors. *Med Oral Patol Oral Cir Bucal*. 2008;13(9).
12. Shear M. Erratum: The aggressive nature of the odontogenic keratocyst: Is it a benign cystic neoplasm? Part 2.Proliferation and genetic studies (*Oral Oncology* (2004) 38:4 (323-331)).*Oral Oncol*. 2004;40(1):107.
13. Heizmann CW. Calcium-binding proteins: basic concepts and clinical implications. *Gen PhysiolBiophys*. 1992;11(5):411–25.
14. Hubbard MJ. Calcium transport across the dental enamel epithelium. *GritRev Oral Biol Med*. 2000;466(4):437–66.
15. Silva SD, Sumathi MK, Balaji N, Shetty NKN, Pramod KM, Cheeramellil J. Evaluation of Calretinin expression in Ameloblastoma and Non-Neoplastic Odontogenic Cysts – An immunohistochemical study. *J Int Oral Heal*. 2013;5(6):42–8.
16. Kalsoom F, Atique M, Ahmed S, Aslam F, Sarfraz T, Jamal S, et al. Calretinin expression in the differential diagnosis of ameloblastoma and keratocystic odontogenic tumour. *Pak Armed Forces Med J*. 2015;65(1):8–12.
17. Sundaragiri SK, Chawda J, Gill S, Odedra S, Parmar G. Calretinin Expression in UnicysticAmeloblastoma: An Aid in Differential Diagnosis. *J Oral Biosci [Internet]*. 2010;52(2):164–9.
18. Alaeddini M, Etemad-Moghadam S, Baghaii F. Comparative expression of calretinin in selected odontogenic tumours: A possible relationship to histogenesis. *Histopathology*. 2008;52(3):299–304.
19. Devilliers P, Liu H, Suggs C, Simmons D, Daly B, Zhang S, et al. Calretinin Expression in the Differential Diagnosis of Human Ameloblastoma and Keratocystic Odontogenic Tumor. *Am J SurgPathol*. 2008;32(2):256–60.
20. Piattelli A, Fioroni M, Rubini C. Calretinin Expression in Odontogenic Cysts. *J Endod*. 2003;29(2):15–7.
21. Vipul Mohan Pawar, Shilpa Patel, JignaPathak, Niharika Swain, RashmiHosalkar JI. Immunohistochemical Evaluation of Calretinin and Cytokeratin-19 in Odontogenic Keratocyst and Ameloblastoma : A Retrospective Study. *J Contemp Dent*. 2015;5(August):98–103.
22. Koneru A, Hallikeri K, Nellithady S. Immunohistochemical Expression of Calretinin in. *ApplImmunohistochemMolMorphol*. 2014;22(10):762–7.
23. AmruthaRudraraju, AparnaVenigalla, Suresh Babburi, PinnisetiSoujanya RVS, Lakshmi KR. Calretinin expression in odontogenic cysts and odontogenic tumors and the possible role of calretinin in pathogenesis of ameloblastoma. *J oral MaxillofacPathol*. 2019;23(3):349–55.

